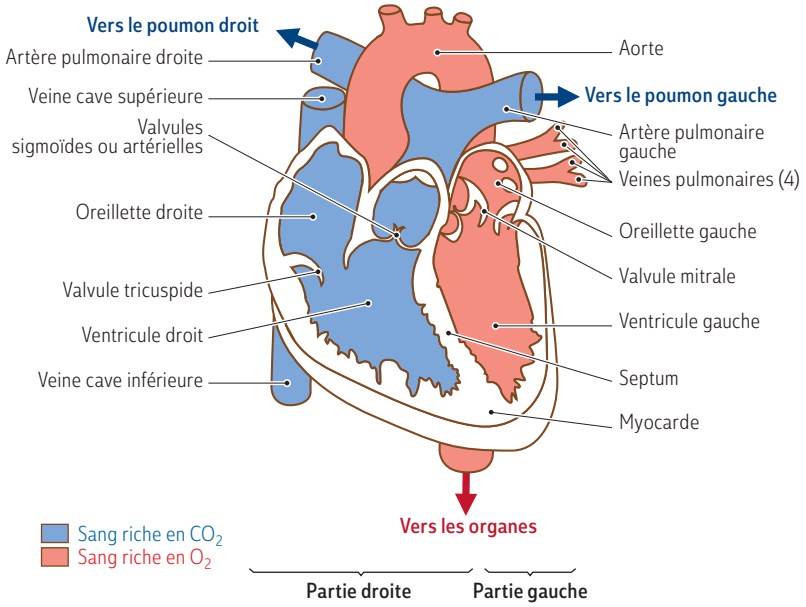

Anatomie du cœur