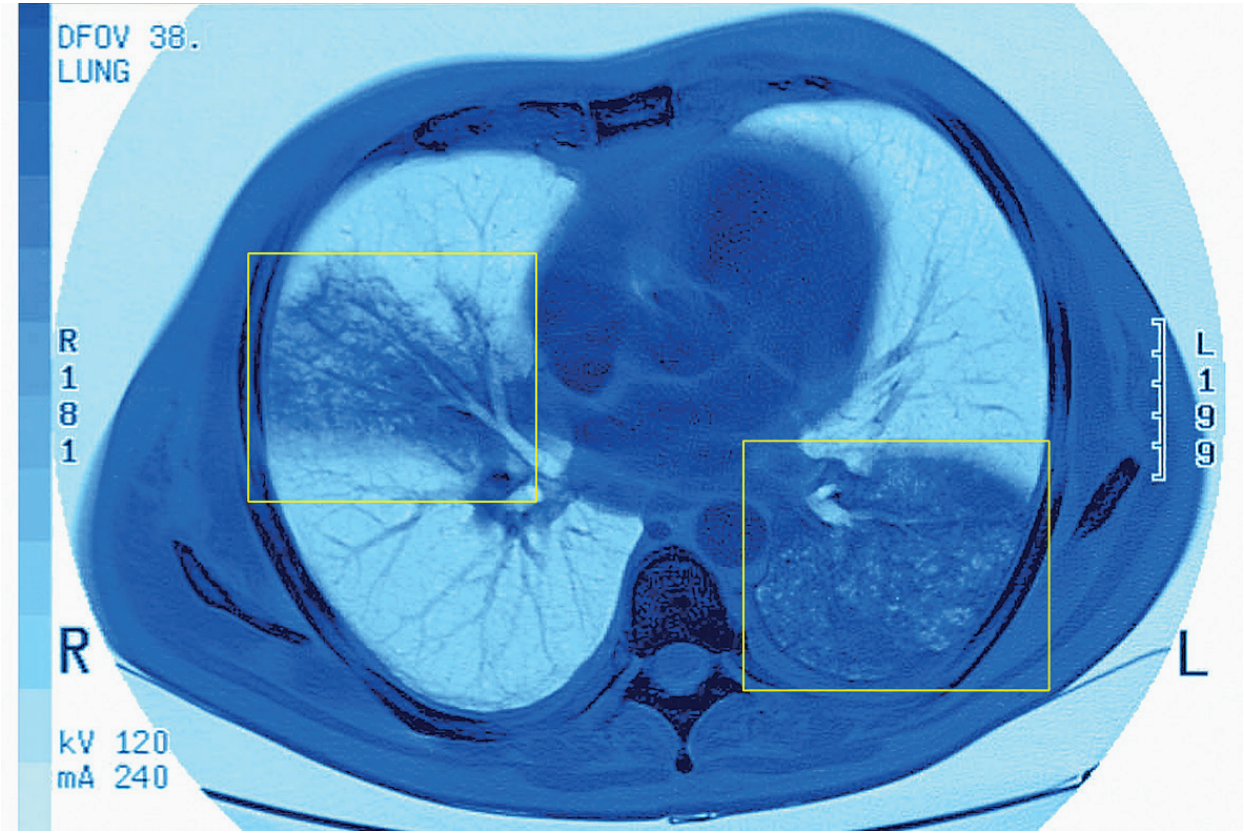

Scanner axial du thorax (pneumonie aiguë affectant les 2 poumons)